Women's & Children's Hospital

# Paediatric Ophthalmology referral guidelines

## Contents


| | |
|---|---|
| Abnormal pupil reaction and size | 2 |
| Abnormal red reflex and or white pupil | 2 |
| Acute eye trauma | 3 |
| Chalazion or Stye | 4 |
| Decreased visual acuity | 5 |
| Droopy eye lid – ptosis | 6 |
| Eye Turns / Squints / Strabismus | 7 |
| Nasolacrimal duct obstruction, sticky and/or watery eyes | |
| Nystagmus or wobbly eye | 9 |
| Red eye or pink eye | 10 |


## Mandatory referral content

**Demographic**

- child's name
- date of birth
- parent/guardian contact details
- referring GP details
- interpreter requirements

**Clinical**

- reason for referral
- clinical urgency
- duration of symptoms
- management to date and response to treatment
- relevant pathology and imaging reports
- past medical history
- current medications
- functional status
- family history

## Priority

Priority will be based upon the information provided in this referral. They will be triaged by a Paediatric Ophthalmology Consultant according to the clinic process and booked accordingly:

**Emergency:** Proceed to the emergency department

**Urgent:** We aim to see these patients as soon as possible

**Semi-urgent/ routine:** Next available appointment. Please note many routine referrals may not be seen at present due to the increasing demand on the service

To help us best triage your referral, it may be returned for further investigations if the following process has not been adhered to.

**Please note this is a guideline for referral only. If concerned about a patient please contact the Ophthalmology Registrar via switchboard on 8161 7000.**

Women's & Children's Hospital

## Abnormal pupil reaction and size

| Initial pre-referral workup | GP management | Guidelines for specialist referral |
|---|---|---|
| **Physical examination**<br>> assess pupil reactions and sizes<br>> check visual acuity if child of a suitable age. If the child is too young, determine if they can fix and follow -(For toddlers try a toy, for infants try a toy or a light). **see also guideline for decreased visual acuity**<br>> check ocular motility - ask child to look up at the roof, down to the ground, and side-to-side. If child too young, try a toy or a light.<br>> perform fundus examination, note presence/absence of red and white reflex **see also guideline for abnormal red reflex/white pupil** | **Treatment**<br>> pre-referral treatment is not recommended for abnormal pupil reaction and size | **Urgent**<br>> asymmetric pupil reactions<br>**Semi urgent**<br>> greater than 1mm difference between the eyes under light-adapted and under dark-adapted conditions. May also be an associated eyelid droop and lighter iris colouration on the side of the smaller pupil<br>> associated limitations of eye movement on the side of the larger pupil<br>**Routine**<br>> less than 1mm difference under light-adapted or dark-adapted conditions |

## Abnormal red reflex and or white pupil

| Initial pre-referral workup | GP management | Guidelines for specialist referral |
|---|---|---|
| **Physical examination**<br>> perform fundus examination, note presence/absence of red and white reflex<br>> assess pupil reactions and sizes. **see also guideline for abnormal pupil reaction and size** | **Treatment**<br>> pre-referral treatment is not recommended for abnormal red reflex or white pupil.<br>**Investigations**<br>> discuss with Ophthalmology registrar on call if immediate (same day) referral to optometrist is warranted for work up | **Urgent**<br>> white or “glowing pupil”<br>> absence of red reflex<br>> **contact on-call ophthalmology registrar via switch board** |

## Acute eye trauma

| Initial pre-referral workup | GP management | Guidelines for specialist referral |
|---|---|---|
| > serious injuries can be disregarded when children present with a painful eye or blurred vision<br>> the following traumatic conditions threaten vision:<br>• ruptured globe<br>• foreign body – (intraocular or deep corneal)<br>• large hyphaemas (causing acute glaucoma)<br>• retinal detachment<br>• corneal burns, (chemical or thermal)<br>• contact lens-related corneal infections (bacterial keratitis)<br><br>**Clinical history**<br>> obtain the following history:<br>• proximity to chemicals or high velocity projectiles<br>• contact lens use<br>• presence of pain, forign body sensation, tearing or photophobia<br>• visual disturbance – temporary or persisting including flashes or floaters in vision<br>• eye discharge<br>• first aid provided | **Treatment**<br>> **please contact the Ophthalmology Registrar via switchboard**<br>> immediate treatment should only be given at the direction of the ophthalmology registrar | **Emergency**<br>**The following presentations all require immediate referral to the Emergency Department. Please contact the Ophthalmology Registrar via switchboard:**<br>> ruptured globe / penetrating eye injury<br>> presence of a foreign body<br>> Hyphaemas (Blood in anterior chamber)<br>> corneal Burns, either chemical or thermal – alkalis penetrate deeper and have a greater potential for serious damage<br>> contact lens related corneal infections (bacterial keratitis)<br>> retinal detachment<br>> blunt trauma resulting in suspected globe rupture<br>> eye lid laceration involving eyelid margin |

## Chalazion or stye

| Initial pre-referral workup | GP management | Guidelines for specialist referral |
|---|---|---|
| **Clinical history**<br>> Chalazia and styes will often disappear on their own | **Treatment**<br>> lump in or beneath the skin of the eye lid<br>• treat with warm compresses (clean, warm washcloth held against closed eyelid) for 2-5 minutes, up to 20 times per day<br>• most will expand in size and then spontaneously rupture. Topical antibiotics are of limited value in this situation<br>> skin around the chalazion/stye appears cellulitic or painful<br>• commence chloramphenicol ointment or drops, or oral antibiotics as appropriate<br>• review in 1-2 days to re-evaluate<br>• if no response to treatment see URGENT REFERRAL<br>**Parent information**<br>> Styes | **Emergency/urgent**<br>> skin around chalazion/stye appears cellulitic or painful and is unresponsive to antibiotic treatment<br>**Routine**<br>> for excision when chalazion / stye is unresponsive to this treatment for more than 3 months |

## Decreased visual acuity

| Initial pre-referral workup | GP management | Guidelines for specialist referral |
|---|---|---|
| **Physical examination**<br>> check visual acuity if child of a suitable age. If the child is too young determine if they can fix and follow (for toddlers try a toy, for infants try a toy or a light). Perform a pinhole test for visual acuity in older children (an improvement in vision may indicate a refractive error).<br>> check ocular motility - ask child to look up at the roof, down to the ground, and side-to-side. If child is too young, use a toy or a light.<br>> perform fundus examination, note presence/absence of red and white reflex. **see also guideline for abnormal red reflex/white pupil**<br>> assess pupil reactions and sizes. **see also guideline for abnormal pupil reaction and size** | **Treatment**<br>> no GP treatment is recommended however all referrals and/or discussions with Ophthalmology registrars should include relevant history including:<br>• length of time of vision loss<br>• surrounding circumstances<br>• accompanying symptoms<br>**Investigations**<br>> for routine/semi-urgent referrals consider referral to optometrist for work up and referral on to ophthalmology<br>**Kid's information**<br>> Problems with eye sight - Blindness | **Emergency**<br>**For all ages**<br>> acute loss of visual acuity<br>> **contact on-call ophthalmology registrar via switch board**<br>**Urgent**<br>**Ages birth - 2 years**<br>> With failure to fix and follow and /or abnormal eye movements<br>**Semi urgent**<br>**Ages 3-5 years**<br>> failed routine screening test Acuity of 6/12 or better is normal<br>**Ages 5-9 years**<br>> failed routine screening test Acuity of 6/9 or better is normal<br>> difference of 2 lines or more between eyes<br>**Routine**<br>**Ages 5-9 years**<br>> decreased acuity in school-age children with developmental delay/autism<br>**Ages 9+ years**<br>> non acute referrals for children aged over 9 years with decreased visual acuity are suitable for referral to a local optometrist |

## Droopy eye lid - ptosis

| Initial pre-referral workup | GP management | Guidelines for specialist referral |
|---|---|---|
| **Physical examination**<br>> assess severity of ptosis - is the eyelid covering any part of the pupil? (See diagram)<br>> check visual acuity if child of a suitable age. If the child is too young determine if they can fix and follow (for toddlers try a toy, for infants try a toy or a light). ***see also guideline for decreased visual acuity***<br>> check ocular motility - whilst holding the eyelids up ask child to look up at the roof, down to the ground, and side-to-side. If child is too young, use a toy or a light.<br>> perform fundus examination, note presence/absence of red and white reflex. ***see also guideline for abnormal red reflex/white pupil***<br>> assess pupil reactions and sizes. ***see also guideline for abnormal pupil reaction and size***<br> 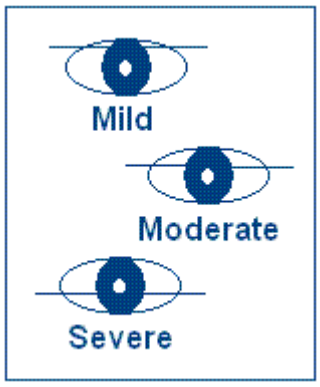 <br> | **Treatment - Neonates**<br>> If all other assessment results are normal reassess in 2 months | **Urgent referral**<br><u>Neonate</u><br>> if assessment results are abnormal or ptosis persists past 2 months of age<br><u>Older infant and child</u><br>> droopy eye lid obstructing vision (moderate – severe)<br>> sudden onset droopy eye lid<br>**Semi urgent**<br>> any child with a droopy eye lid that does not obstruct the pupil (mild)<br>**Routine**<br>> older child (aged over 9 years) with history of congenital droopy eye lid |

## Eye turns / squints / strabismus

| Initial pre-referral workup | GP management | Guidelines for specialist referral |
|---|---|---|
| **Physical examination**<br>Please check the following:<br>> check visual acuity if child of a suitable age. If the child is too young determine if they can fix and follow (for toddlers try a toy, for infants try a toy or a light). **see also guideline for decreased visual acuity**<br>> check ocular motility - ask child to look up at the roof, down to the ground, and side-to-side. If child too young, use a toy or a light.<br>> perform fundus examination, note presence/absence of red and white reflex. **see also guideline for abnormal red reflex/white pupil**<br>> assess pupil reactions and sizes. **see also guideline for abnormal pupil reaction and size**<br>> note any behavioural issues (was the child hard to assess, do they have a history of ADHD or autism etc) | **Initial findings**<br>**Please see guidelines for referral with findings from your examination**<br>> do not refer for infants less than 3 months of age with intermittent/variable turning in of the eye - this is normal for infants.<br>**Parent information**<br>> Turned eyes (squint) | **Urgent**<br>> true acute onset of constant eye turning (esotropia or exotropia) at any age<br>**Semi urgent**<br>> intermittent/variable esotropia older than 3 months of age<br>> constant large esotropia all ages<br>**Routine**<br>> intermittent/constant exotropia of the eye<br>> constant long standing esotropia in children older than 9 years of age |

## Nasolacrimal duct obstruction, sticky and/or watery eyes

| Initial pre-referral workup | GP management | Guidelines for specialist referral |
|---|---|---|
| **Physical examination**<br>**Birth - 2 weeks**<br>> acute sticky eye with severe amounts of discharge: **IMMEDIATE REFERRAL to EMERGENCY**<br>**Neonates**<br>> neonates with visible dilation of lacrimal sac and bluish discoloration of overlying skin: **IMMEDIATE REFERRAL to Emergency - for sepsis concerns**<br>**Ages 2 - 12 months**<br>> with chronic tearing and discharge:<br>please do not refer for probing until patients are over 12 months of age *unless* discharge is severe and causing skin irritation. Treat medically (as outlined).<br>**12 months onwards**<br>> patients with increased tearing that persists past 12 months of age:<br>treat medically (as outlined). Refer *only* if symptoms persist for more than 3 months. | **Treatment**<br>> massage the nasolacrimal sac<br>> keep the eye clean - wash with salt water as needed<br>> apply warm compresses (clean, warm washcloth held against closed eyelid for 2-5 minutes, daily<br><br>**Parent information**<br>> Your baby's eyes – blocked tear duct | **Emergency**<br>> **contact on-call ophthalmology registrar via switchboard**<br>> neonates with visible dilation of lacrimal sac and bluish discoloration of overlying skin<br>> acutely sticky eye with severe amounts of discharge in patients aged 2 weeks and younger<br>**Semi urgent**<br>> severe discharge with associated skin irritation in patients under 12 months of age<br>**Routine**<br>> symptoms persisting longer than 3 months for patient over 12 months of age |

## Nystagmus – wobbly eye

| Initial pre-referral workup | GP management | Guidelines for specialist referral |
|---|---|---|
| **Physical examination**<br>Please check the following:<br>> assess for albinism (characterised by white hair, pale skin and iris transillumination)<br>> perform fundus examination, note presence/absence of red and white reflex. **see also guideline for abnormal red reflex/white pupil**<br>> check visual acuity if child of a suitable age. If the child is too young determine if they can fix and follow (for toddlers try a toy, for infants try a toy or a light). **see also guideline for decreased visual acuity** | **Treatment**<br>> pre-referral treatment is not recommended for nystagmus | **Urgent**<br>> sudden or acute onset<br>> present since infancy but absent red reflex<br>**Semi urgent**<br>> present since infancy with red reflex present |

## Red eye or pink eye

| Initial pre-referral workup | GP management | Guidelines for specialist referral |
|---|---|---|
| **Physical examination**<br>For children presenting with a red or pink eye, please do the following:<br>> carefully inspect the eyelids, everting to examine the under surface and check for foreign bodies<br>> stain with fluoroscein to check for corneal abrasions or ulcers<br>**Clinical History**<br>> Obtain the following history:<br>• possibility of ocular trauma<br>• contact lens use<br>• presence of pain,<br>• duration of the redness<br>• presence of itch<br>• discharge | **Treatment**<br>> purulent discharge<br>• treat with eye toilet and topical chloramphencil.<br>• if neonate older than 3 weeks review treatment after 3 days<br>> child complains of itchiness, eyelid swelling and redness, watery discharge<br>• treat with antihistamines (oral or topical) and artificial tears as needed<br>**Parent information**<br>> Conjunctivitis | **Emergency**<br>**The following presentations all require immediate referral to the Emergency Department. Please contact the Ophthalmology Registrar via switchboard.**<br>> pain or Photophobia<br>> extensive subconjunctival haemorrhage<br>> reduced vision<br>> corneal opacity<br>> purulent discharge:<br>• not settling with treatment<br>> neonate less than 3 weeks old<br>> unilateral eyelid swelling and redness |

## For more information

**Women's and Children's Hospital**
**72 King William Road**
**North Adelaide SA 5006**
**Telephone: (08) 8161 7000**
**www.wch.sa.gov.au**



Government of South Australia
SA Health

Women's & Children's Hospital